

# Integrative Cancer Therapies

<http://ict.sagepub.com>

---

## **A Retrospective Evaluation of the Effects of Deuterium Depleted Water Consumption on 4 Patients with Brain Metastases from Lung Cancer**

Krisztina Krempels, Ildikó Somlyai and Gábor Somlyai

*Integr Cancer Ther* 2008; 7; 172

DOI: 10.1177/1534735408322851

The online version of this article can be found at:  
<http://ict.sagepub.com/cgi/content/abstract/7/3/172>

---

Published by:



<http://www.sagepublications.com>

**Additional services and information for *Integrative Cancer Therapies* can be found at:**

**Email Alerts:** <http://ict.sagepub.com/cgi/alerts>

**Subscriptions:** <http://ict.sagepub.com/subscriptions>

**Reprints:** <http://www.sagepub.com/journalsReprints.nav>

**Permissions:** <http://www.sagepub.com/journalsPermissions.nav>

**Citations** <http://ict.sagepub.com/cgi/content/refs/7/3/172>

# A Retrospective Evaluation of the Effects of Deuterium Depleted Water Consumption on 4 Patients with Brain Metastases from Lung Cancer

Krisztina Krempels, MD, Ildikó Somlyai, MSc, and Gábor Somlyai, PhD

**Hypotheses.** Because of the number of sufferers and high mortality rate, the standard care and new therapeutic options in the treatment of brain metastasis from lung cancer are the subject of intense research. A new concept based on the different chemical and physical behavior of protium and deuterium affecting cell signaling and tumor growth has been introduced in the treatment of cancer patients. The aim of this study was to investigate the impact of deuterium depleted water (DDW) consumption in addition to conventional forms of therapy on the survival of lung cancer patients with brain metastasis. **Study design.** A series of 4 case histories was retrospectively evaluated. The patients were diagnosed with brain metastasis deriving from a primary lung tumor and started consuming DDW at the time of or after the diagnosis of the brain metastasis, which was inoperable or the surgical intervention did not result in complete regression. The primary objective was survival. **Methods.** The daily water intake of the patients was replaced with DDW, which complemented the conventional forms of treatment. Patients were consuming DDW for at least 3

months. The treatment was continued with DDW of 10 to 15 to 20 ppm lower deuterium (D) content every 1 to 2 months and thus a gradual decrease was maintained in the D-concentration in the patient's body. **Results.** DDW consumption integrated into conventional treatments resulted in a survival time of 26.6, 54.6, 21.9, and 33.4 months in the 4 patients, respectively. The brain metastasis of 2 patients showed complete response (CR), whereas partial response (PR) was detected in 1 patient, and the tumor growth was halted (no change or NC) in 1 case. The primary tumor of 2 patients indicated CR, and the lung tumor in 2 patients showed PR. **Conclusions.** DDW was administered as an oral anticancer agent in addition to conventional therapy, and noticeably prolonged the survival time of all 4 lung cancer patients with brain metastasis. We suggest that DDW treatment, when integrated into other forms of cancer treatment, might provide a new therapeutic option.

**Keywords:** lung cancer; deuterium depletion; deuterium depleted water; brain metastasis; survival

Lung cancer is the leading cause of cancer-related death in men and women. A high percentage of lung cancer patients develop brain metastases resulting in poor prognosis. For a solitary brain metastasis surgical resection, and in the event of multiple metastases, whole brain irradiation (WBI) is considered standard treatment. In addition, aggressive management approaches, including surgical resection with or without WBI or nonsurgical approaches using stereotactic radiosurgery on its own or together with WBI, are standard treatments.<sup>1,2</sup>

The majority of clinical trials indicate a median survival time (MST) of 4 to 6 months for patients with brain

metastasis from lung cancer.<sup>3</sup> A considerably longer survival time was achieved only by patients with limited symptoms of the disease who were newly diagnosed thoracic stage I patients bearing a solitary brain metastasis. This subgroup of patients underwent successful brain surgery or stereotactic radiosurgery followed by WBI and achieved an MST of 25.6 months, whereas in patients with a locally advanced primary disease an MST of 9.9 months was achieved.<sup>4</sup> In a trial on stereotactic radiosurgery involving consecutive patients, including those suffering from advanced primary lung cancer and/or multiple brain and/or other distant metastases, the overall MST remained 7.0 months.<sup>5</sup> In a study on recurrent small cell lung carcinoma (SCLC) with brain metastases<sup>6</sup> MST was prolonged by as much as 18 months using radiosurgery. The administration of gefinitib, a tyrosine kinase inhibitor, led to the regression of brain metastases and resulted in an MST of

From HYD LLC for Cancer Research and Drug Development, Budapest, Hungary.

Address correspondence to: Gábor Somlyai, PhD, HYD LLC for Cancer Research and Drug Development, Ménesi út 104, H-1118 Budapest, Hungary; e-mail: [gsomlyai@hyd.hu](mailto:gsomlyai@hyd.hu).

8.3 months.<sup>7,8</sup> There are only a few exceptional cases when patients with brain metastasis from lung cancer survived for a period longer than 5 years.<sup>9,10</sup>

The stable isotopes of hydrogen, deuterium (D) and protium (H), have different chemical and physical behavior.<sup>11-13</sup> Bearing in mind that the D-concentration in living organisms is 12 mmol/L and to investigate its possible role in cell cycle regulation, numerous studies have been conducted on cell lines in media prepared with deuterium depleted water (DDW) which proved the pivotal role of D in cell signaling and tumor growth.<sup>14,15</sup> Animals bearing xenotransplanted or spontaneous malignancies were successfully treated by the per os (PO) administration of DDW.<sup>15,16</sup> The apoptosis-triggering effect of DDW was detected both in vitro<sup>15</sup> and in vivo.<sup>16</sup> D-depletion also exerts an influence on proto-oncogenes and tumor suppressor genes, and the expression of *c-myc*, *Ha-ras*, and *p53* genes induced by carcinogen exposure was significantly weakened when the animals were given DDW to drink.<sup>17</sup> The therapeutic effectiveness of DDW consumption was also confirmed in a human phase II double blind clinical trial.<sup>18</sup> The Hungarian National Institute of Pharmacy authorized the administration of DDW for compassionate use in the treatment of cancer in its advanced stages. The aim of the study was to collect information with regard to the potential usefulness of PO DDW therapy alongside conventional forms of treatment in lung cancer patients with brain metastases. We decided to present this subset of patients because of the poor predicted life expectancy, which is coupled with high risk of emergency complications. The blood-brain barrier might impede delivery of conventional chemotherapeutic agents into brain metastases, therefore the treatment options and strategies are also limited. Oral exposure to D-enriched water in mice showed that besides other organs, brain incorporates D as chemically bound hydrogen. The D content of the body fluids falls rapidly to baseline levels when the D<sub>2</sub>O is withdrawn from the diet and consequently the incorporated D of nonaqueous tissues is also released,<sup>19</sup> suggesting that the water easily permeates across the blood-brain barrier. The new submolecular treatment modality of D depletion is able to exert its effect on the central nervous system as well.

We suggest that the integration of DDW treatment into conventional therapies may improve the chances of survival of lung cancer patients after the diagnosis of the brain metastasis.

## Methods

### Design, Eligibility, and Recruitment

A series of 4 case histories was evaluated retrospectively. The primary end point was survival and the response to the combined treatment was also set as a secondary end point. A total of 24 lung cancer patients suffering from brain metastasis

were supplied with DDW between August 1993 and December 2005 in Hungary. Patients considered eligible to take part in the study were those (a) who were diagnosed with brain metastasis deriving from a primary lung tumor; (b) who started consuming DDW at the time of or after the diagnosis of the brain metastasis, that is, the first brain metastasis did not develop during the DDW treatment; (c) whose brain metastasis was inoperable or the surgical intervention did not result in complete regression (CR); and (d) who consumed DDW for at least 3 months. In all, 4 patients met the study criteria. Patients were made aware of the available information regarding DDW treatment.

### DDW Production

DDW was produced from ordinary water containing the natural amount of D (150 ppm, equivalent to 16.8 mmol/L) using fractional distillation<sup>20</sup> to decrease the D concentration in the range of 95 to 25 ppm, depending on the tray number of the distillation tower. Mineral salts were supplemented in the same way as in ordinary drinking water. DDW-25 contains 3.8 mg/L of KCl, 181.5 mg/L of MgCl<sub>2</sub>·6H<sub>2</sub>O, and 262.5 mg/L of CaCl<sub>2</sub>·2H<sub>2</sub>O. DDW-25 was used to prepare drinking water with 105 ppm and 85 ppm by mixing DDW-25 with mineral water in ratios of 0.36:0.64 or 0.52:0.48, respectively. D concentration was determined by infrared spectroscopy with a precision of ±3 ppm with a Foxboro Miran 1A CVF IR spectrophotometer (at a 4-μm wavelength, in a 0.2-mm CaF<sub>2</sub> cell).

### Treatment

The PO DDW treatment supplemented conventional therapy of radiotherapy and/or chemotherapy and/or surgery but did not substitute it. The aim of the treatment was to reduce the D concentration in the patient's body by replacing the ordinary water intake with DDW. The dosage of DDW is directly proportional to the daily volume of the DDW consumed and to the difference in D concentration between ordinary water and DDW consumed. The body weight affects inversely the dosage. The concentration gradient between the patient's body and the DDW to be consumed has to be restored repeatedly during the course of treatment. Therefore, the treatment was continued with DDW of a 10 to 15 to 20 ppm lower D content every 1 to 2 months. The continuous decrease in D concentration in the patient's body was maintained for the longest time period possible, that is, for 6 to 10 months. When a further decrease in D concentration in the body can no longer be achieved, the aim is to constantly keep it at the lowest possible level. To achieve the best result, any increase in DDW dosage may be postponed until the current cycle of conventional therapy has been completed. The course of DDW consumption was monitored on a monthly basis; the volume of the DDW

**Table 1.** Patients' Characteristics and Time Intervals (in Months) Showing the Course of Treatment With DDW and the Follow-up

Patient ID	Lung Tumor	Thoracic Stage	Brain Metastasis	Time <sup>a</sup>	Duration <sup>b</sup>	Follow-up <sup>c</sup>	Follow-up <sup>d</sup>
1	NSCLC	T3N0M0; stage II	Multiple	0	17.5	9.1	26.6
2	SCLC	T2N0M0; stage II	Solitary	0.3	44.4	10.2	54.6
3	NSCLC	T2N2M1; stage IV	4 metastases	1	9.7	0	9.7
4	NSCLC	T1N0M0; stage I	2 metastases	0	31.7	1.7	33.4

NOTES: DDW = deuterium depleted water; NSCLC = non-small cell lung carcinoma; SCLC = small cell lung carcinoma.

<sup>a</sup> Time (in months) from the diagnosis of the brain metastasis to the start of DDW therapy.

<sup>b</sup> Duration (in months) of DDW therapy.

<sup>c</sup> Follow-up time (in months) from the end of DDW therapy.

<sup>d</sup> Follow-up time (in months) from the start of DDW therapy.

consumed and the D concentration (ppm) was entered in the records during the follow-up.

## Results

One patient with solitary and 3 patients with multiple brain metastases from primary lung tumors underwent PO DDW treatment alongside conventional forms of cancer therapy. The data describing the DDW treatment and the follow-up are detailed in Table 1. DDW treatment was initiated immediately following the diagnosis of the brain metastasis in 2 cases. DDW treatment commenced 10 days (patient 2) and 26 days (patient 3) after the confirmation of the brain tumor. The duration of DDW therapy was 17.5, 44.3, 9.7, and 31.7 months in patients 1, 2, 3, and 4, respectively. Patients 2 and 3 were alive when the follow-up ended, 54.6 and 9.7 months after the detection of the brain metastasis. Patients 1 and 4 achieved survival times of 26.6 and 33.4 months, respectively. The treatment resulted in CR of 2 patients' brain metastases (patients 1 and 2). One brain metastasis in patient 4 showed CR and the second decreased significantly in size (partial response, PR). Furthermore, the combined treatment halted the progression (no change, NC) of the multiple brain tumors in patient 3. CR of the primary lung tumor was diagnosed in patient 2. Patient 4 had no relapse of her lung carcinoma for 2 years when she consumed DDW. The other 2 patients' lung cancer decreased significantly in size (PR) during the study.

Major medical complications, that is, increased intracranial pressure (patients 1 and 4), superior vena cava syndrome and thrombophlebitis (patient 3) were observed when the patients joined the study. A poor prognosis of survival time of no more than 3 months was made for patient 2. According to the prognostic classes of the recursive partitioning analysis, which focuses on the survival of lung cancer patients with brain metastases, each patient met the criteria of class 3 indicating dismal survival.<sup>21</sup> We applied staging to only the primary site and metastases affecting organs other than the brain, which allows a more precise evaluation of the patient's general

condition and showed that except for patient 4, the disease was diagnosed in later stages (Table 1). Histological examinations revealed non-small cell lung carcinoma (NSCLC) in 3 patients, whereas the tumor in patient 2 was diagnosed as SCLC.

## Case Histories

In the following sections, we shall report the detailed case histories of the 4 lung cancer patients. To enable a better understanding of each individual case we have indicated the number of days that elapsed between the initiation of DDW treatment and each event mentioned by an asterisk (\*).

### Patient 1

Patient 1 was a 45-year-old man, and a summary of his case history is presented in Table 2. An emergency complication of increased intracranial pressure developed in November 2001. One 30-mm cerebellar metastasis and numerous 5-mm metastases were detected by computed tomography (CT) and magnetic resonance imaging (MRI) scans. The primary NSCLC, 60 × 40 mm in size at thoracic stage T3N0M0, had already spread to the pleura and the right third rib. It was sitting in the right upper lung lobe. DDW treatment using DDW containing 105 ppm D was initiated on diagnosis. The 20 × 20 × 30 mm multicenter cerebellar metastasis was excised at the end of November 2002 (16 days\*), whereas the 5-mm alterations remained unoperated. The patient underwent WBI of 30 Gray followed by a reduction in the D content of DDW to 97 ppm (44 days\*), which resulted in the expectoration of considerable amounts of sputum. In January 2002 (84 days\*) PR was observed in the brain; postoperative residues and small metastases causing neither compression nor edema were detected using CT and MRI. A CT scan of the lung revealed an increase in the size of the tumor to 68 × 53 mm (progressive disease, PD). The D content of DDW was decreased to 89 ppm (86 days\*) resulting in an evening fever (37.8°C) that ceased spontaneously. Carboplatinum-etoposide chemotherapy was

**Table 2.** Summary of the Case History of Patient 1

Date	Status	DDW Treatment	Conventional Therapy	Notes
November 2001	Multiplex cerebellar metastases, NSCLC	105 ppm	Dehydration therapy followed by excision of 1 metastasis	Increased intracranial pressure
December 2001		97 ppm	Radiotherapy	Sputum
January 2002	PR brain; PD lung	97 ppm		
February 2002		89 ppm		Fever
March 2002		89 ppm	Chemotherapy	
April 2002	CR brain	89 ppm		
May 2002	CR brain; PR lung	89 ppm		
August 2002		89 ppm	Thoracic exploration	Lung inoperable
September 2002		89 ppm	Chemotherapy	
October 2002		84 ppm		
December 2002		84 ppm	Radiotherapy (thorax)	
January 2003		84 ppm	Radiotherapy (thorax)	
April 2003		End of DDW treatment		
January 2004	The patient died			

NOTES: DDW = deuterium depleted water; NSCLC = non-small cell lung carcinoma; PR = partial response; PD = progressive disease; CR = complete response.

initiated in March 2002 (116 days<sup>\*</sup>). The 4-month therapy resulted in CR of the brain metastases. A CT scan in May 2002 (190 days<sup>\*</sup>) revealed that the lung tumor had shrunk to 50 mm in diameter (PR). In August 2002 (293 days<sup>\*</sup>) thoracic exploration revealed that the primary tumor had already spread to the mediastinum and infiltrated the superior caval vein. This was followed during the next 6 months by gemcitabine chemotherapy starting in September 2002 (318 days<sup>\*</sup>), a reduction in the D content of DDW to 84 ppm in October 2002 (343 days), and thoracic irradiation in December 2002 and January 2003. By February 2003 (465 days<sup>\*</sup>) the patient had gained 4 kg in weight. DDW treatment was terminated in April 2003 (524 days<sup>\*</sup>). During the 17.5 months of DDW therapy, the patient enjoyed a good quality of life. He died in January 2004, more than 2 years after his brain metastases had been diagnosed and 9.1 months after he had stopped drinking DDW.

In summary, the patient suffered from multiple cerebellar metastases, which led to an emergency complication of increased intracranial pressure. The primary site, an advanced adenocarcinoma of the lung, was subsequently diagnosed. The patient consumed DDW for 524 days and died 797 days after the first diagnosis. The administration of DDW along with conventional forms of treatments resulted in CR of the brain metastases and PR of the inoperable lung adenocarcinoma.

### Patient 2

A summary of the case history of patient 2, a 54-year-old woman, is presented in Table 3. A CT scan in July 2001 detected a 20 × 30 × 40 mm metastatic parieto-occipital tumor, which resulted in problems with vision and moderate compression of the lateral ventricle (Figure 1). The primary site was identified in the lung: a 30 × 50 × 32 mm

SCLC at thoracic stage T2N0M0 was detected in the second and third segments of the right lung. Aggressive combined treatment of radiotherapy to the thorax and the skull at a dose of 70 Gray each, 6 cycles of cisplatin-epidoxifen chemotherapy, and consumption of DDW containing 105 ppm D were initiated. Radiotherapy was completed in October 2001 (89 days<sup>\*</sup>) and chemotherapy in May 2002 (249 days<sup>\*</sup>), whereas the first phase of DDW consumption was prolonged until June 2003 (705 days<sup>\*</sup>). In October 2001 (89 days<sup>\*</sup>), the occipital tumor decreased in size to 23 × 15 × 20 mm and the compression of the lateral ventricle ceased (PR; Figure 2.). In March 2002 (229 days<sup>\*</sup>), the occipital tumor shrank to 16 × 13 × 15 mm in size (PR). A chest X-ray examination revealed PR in January 2002 (176 days<sup>\*</sup>), and the patient was free of any complaints and symptoms. The D content of DDW was adjusted to 85 ppm at the end of March 2002 (249 days<sup>\*</sup>), and after the completion of the chemotherapy it was gradually decreased to 50 ppm by December 2002 (493 days<sup>\*</sup>). As a result of the prolonged DDW treatment, the size of the tumor decreased continuously and in February 2003 (365 days<sup>\*</sup>) CR was diagnosed in the primary and the metastatic site. DDW treatment was first interrupted for 2 months in June 2003 (705 days<sup>\*</sup>) followed by treatment with DDW with a D content of 75 ppm and then 62 ppm for 1½ months each. In February 2005, a CT scan confirmed CR in the brain; residual tissue without signs of malignancy was diagnosed in the previously affected area (Figure 3). The next course of DDW treatment was scheduled in February 2005 (1290 days<sup>\*</sup>) with DDW having a D content of 105 ppm for 2 months followed by a 1-month course of treatment with DDW containing 85 ppm D. Five years after the diagnosis of the brain metastasis the patient continues to lead an active life and is still in remission.

To sum up, the parieto-occipital tumor causing vision problems developed as a metastasis of an SCLC in the



**Table 3.** Summary of the Case History of Patient 2

Date	Status	DDW Treatment	Conventional Therapy	Notes
July 2001	Solitary parieto-occipital metastasis, SCLC	105 ppm	Radiotherapy (thorax + skull), chemotherapy	Vision problems, predicted life expectancy of 3 months
October 2001	PR brain	105 ppm	End of radiotherapy, chemotherapy	
January 2002	PR lung	105 ppm	Chemotherapy	No complaints or symptoms
March 2002	PR brain continued	85 ppm	Chemotherapy	
May 2002		85 ppm	End of chemotherapy	
December 2002	PR brain continued; PR lung continued	50 ppm		
February 2003	CR brain; CR lung continued	50 ppm		
June 2003	Status idem	Interrupted for 2 months		
August 2003		75 ppm		
October 2003		62 ppm		
December 2003	Status idem	None		
October 2004	Status idem	None		
February 2005		105 ppm		
April 2005		85 ppm for 1 month		
May 2006	No relapse			
August 2006	No relapse			The patient has led an active life

NOTES: DDW = deuterium depleted water; SCLC = small cell lung carcinoma; PR = partial response; CR = complete response.

right lung. DDW treatment was initiated concurrently with conventional treatment, which was followed for several years by the consumption of DDW on its own for a total of 1331 days. The process of both the primary lung tumor and brain metastasis resulted in CR during the prolonged DDW administration. The patient was still alive when the study was closed and up to the present time she has been monitored for 1638 days.

### Patient 3

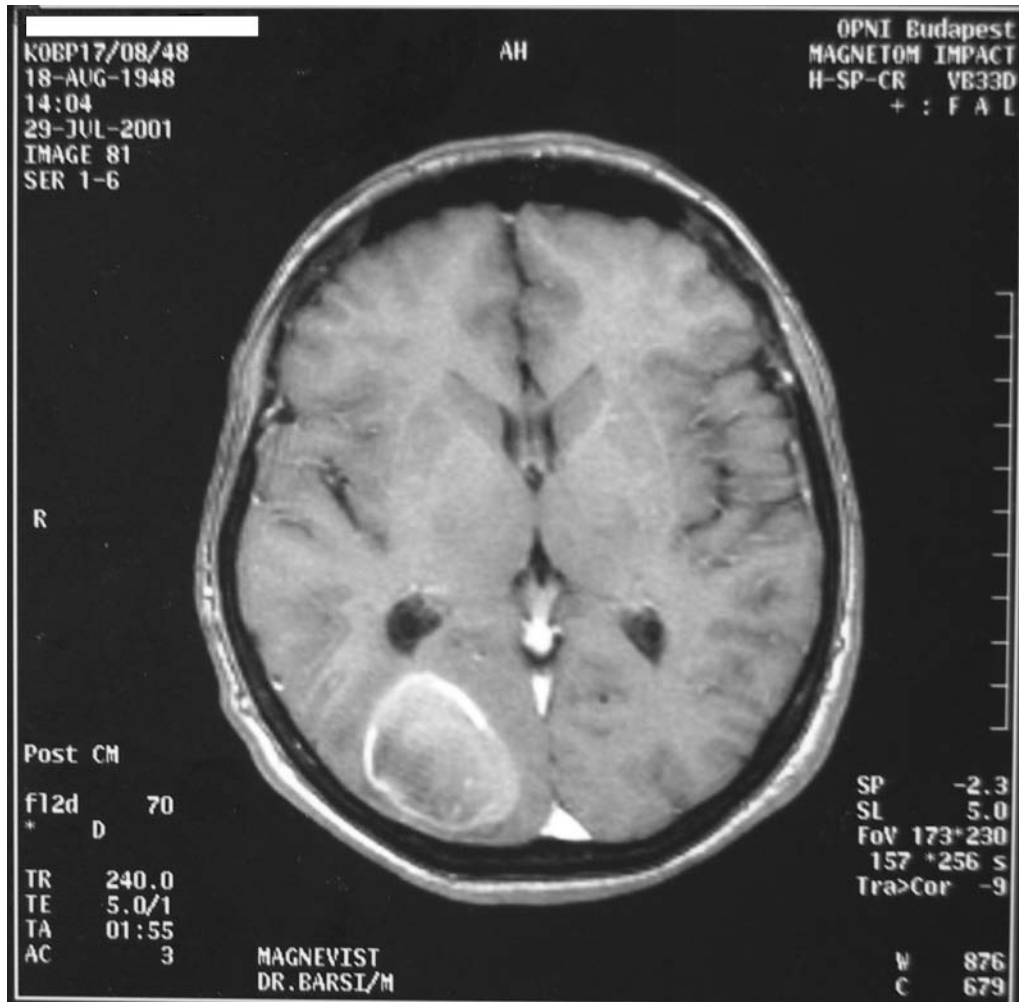
Table 4 presents a summary of the case history of patient 3, a 41-year-old man. After 4 brain metastases had been detected in December 2001, NSCLC adenocarcinoma staged at T2N2M1 in the right lung was diagnosed resulting in metastasis in the adrenal gland. One cerebellar tumor out of the 4 brain metastases was excised and then WBI and gemcitabine-cisplatin chemotherapy was initiated. Despite the intense treatment administered, the illness progressed spreading to the left supraclavicular lymph nodes. Thrombophlebitis in the leg and superior vena cava syndrome also developed. The subsequent prognosis was a further survival time of 3 weeks. Treatment with DDW with a D content of 105 ppm was initiated in January 2002 resulting in stagnation of the brain metastases (NC). It was recommended that the D content of the DDW be adjusted to a lower level in March 2002 (64 days\*). Because of an inaccurate dilution of DDW containing 25 ppm D, the patient drank DDW containing 120 ppm D, which is even closer to the natural level, so instead of the dose being increased, it was in fact

lowered. The D content was corrected to 62 ppm in April 2002 (109 days\*). Although the illness was in its advanced stages, the patient enjoyed a reasonable quality of life and he could manage gentle physical exercise (angling). A chest X-ray in May 2002 (123 days\*) detected signs of regression (PR) in the mediastinum, whereas the primary tumor itself stagnated (NC). The D content of the DDW was decreased to 50 ppm at the end of May 2002 (133 days\*). Chemotherapy was completed (173 days\*) and then followed by 16 courses of radiotherapy in August 2002 (203 days\*), but progression was observed by a chest X-ray (PD). The patient experienced pain in the legs and back and he was almost completely unable to walk. The D content of the DDW was decreased to 37 ppm. The patient was hospitalized and no further information could be obtained about him, which left us with no option but to close his file.

Briefly, the patient suffered from multiple brain metastases, which caused life-threatening complications. The primary tumor, an advanced, inoperable adenocarcinoma in the right lower lobe of the lung, was subsequently diagnosed. When he joined the study, the patient's life expectancy was 3 weeks. DDW treatment lasting 292 days combined with conventional therapy resulted in PR of the lung tumor and NC of the brain metastases.

### Patient 4

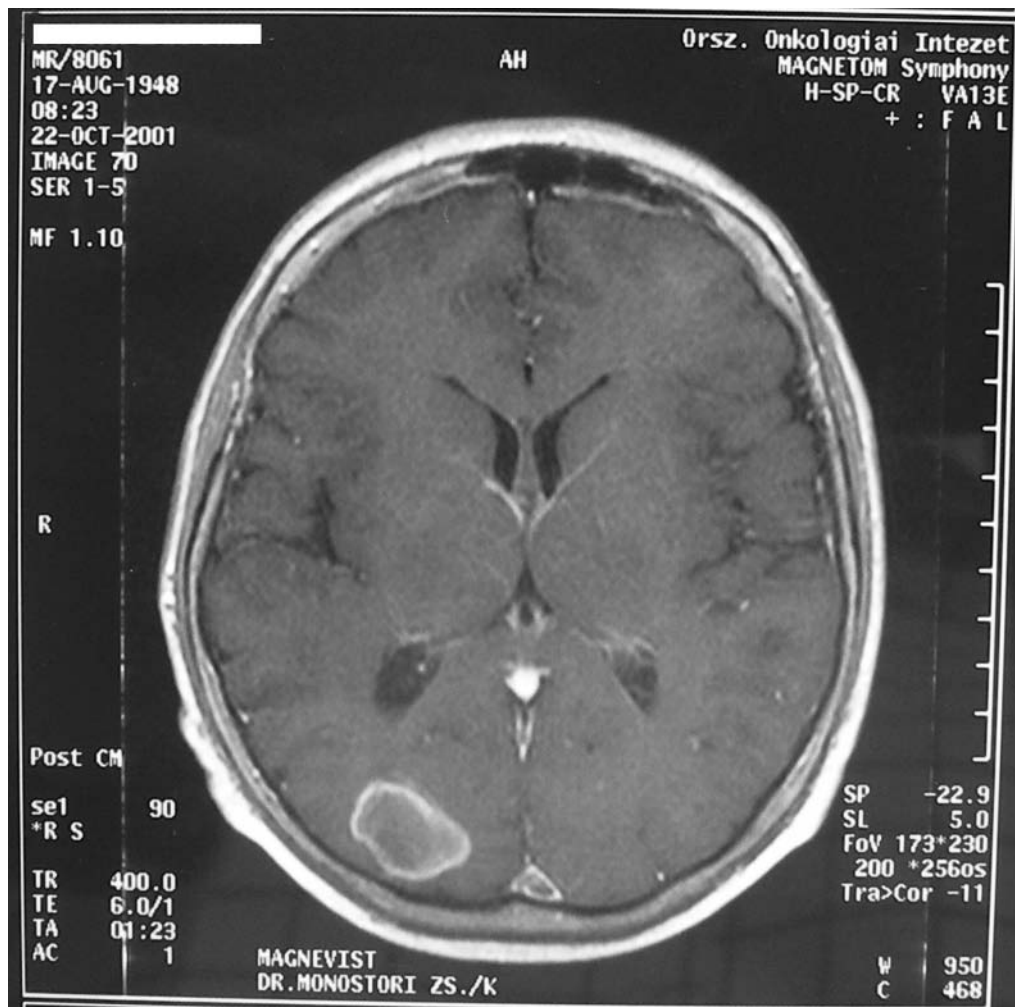
Patient 4 was a 61-year-old woman and a summary of her case history is presented in Table 5. The NSCLC adenocarcinoma at stage T1N0M0 in the right lower lobe was



**Figure 1.** Anteroposterior computed tomography (CT) image of the brain metastasis from lung cancer in patient 2 before the treatment. The anteroposterior CT image of the brain shows on the right side a metastatic parieto-occipital tumor measuring  $20 \times 30 \times 40$  mm before the combined treatment of radiotherapy and chemotherapy supplemented with deuterium depleted water (DDW) consumption.

diagnosed and resected in June 1997. No relapse or metastases were detected during the next 4 years. Impairment of the cognitive functions, aphasia, headache, and nausea developed in the summer of 2001. A CT scan in December 2001 revealed 2 inoperable metastases causing increased intracranial pressure: one  $45 \times 40$  mm alteration in the left temporal region and a second 20-mm tumor in the right frontoparietal region. Stereotactic brain irradiation and treatment with DDW containing 105 ppm D were initiated. The D content was decreased to 85 ppm at the end of January 2002 (47 days<sup>\*</sup>) and to 65 ppm in April 2002 (121 days<sup>\*</sup>). By March 2002 (90 days<sup>\*</sup>), the tumor size of both metastases (PR) had decreased and the right frontoparietal tumor showed CR in April 2002 (121 days<sup>\*</sup>). An MRI scan was first carried out in May 2002 (166 days<sup>\*</sup>) and this detected multiple tumors occupying a large area in the left temporomedial region, revealed PR

of the previously described left temporal alteration, which had decreased to  $20 \times 15 \times 15$  mm, and confirmed CR in the right side. The surgical excision of the temporal metastasis became feasible in September 2002 (264 days<sup>\*</sup>). Prior to surgery the patient drank DDW with a D content of 25 ppm and she was advised to interrupt DDW treatment for 3 weeks. Treatment with DDW having a D content of 105 ppm was in fact resumed at the end of January 2003 (408 days<sup>\*</sup>), when 2 small relapses requiring stereotactic radiotherapy were detected in the brain. By March 2003 (455 days<sup>\*</sup>) the patient had once again achieved PR and was in good health. This status in the brain was maintained for 6 months by decreasing the D content of DDW to 85 ppm in March (455 days<sup>\*</sup>), to 75 ppm in May 2003 (508 days<sup>\*</sup>), and to 62 ppm in July 2003 (577 days<sup>\*</sup>). In September 2003, (639 days<sup>\*</sup>) a new  $12 \times 13$  mm alteration developed in the margin of the resection cavity (PD).



**Figure 2.** Anteroposterior computed tomography (CT) image of the brain metastasis from lung cancer in patient 2 after 3 months of deuterium depleted water (DDW) consumption and the completion of radiotherapy and chemotherapy.

After 3 months of DDW consumption and completion of the combined radiotherapy and chemotherapy, the tumor decreased in size to  $23 \times 15 \times 20$  mm.

Both stereotactic irradiation and treatment with DDW of a lower D content was initiated. Although the thoracic process had spread to the contralateral lung by November (690 days\*; PD), as a result of the aggressive treatment consisting of DDW consumption and chemotherapy followed by thoracic irradiation, the process was converted into PR in February 2004 (788 days\*). Permanent PD in the brain was observed, a new brain metastasis developed in May 2004 (885 days\*; PD), and the patient suffered from decreased consciousness. In addition to DDW ordinary tap water was consumed, and the patient was advised to change to DDW containing 25 ppm D in June 2004 (920 days\*). DDW consumption was finally stopped in July 2004 (951 days\*). The patient died in September 2004, a period of 1003 days (33.4 months) after the diagnosis of the inoperable brain metastases.

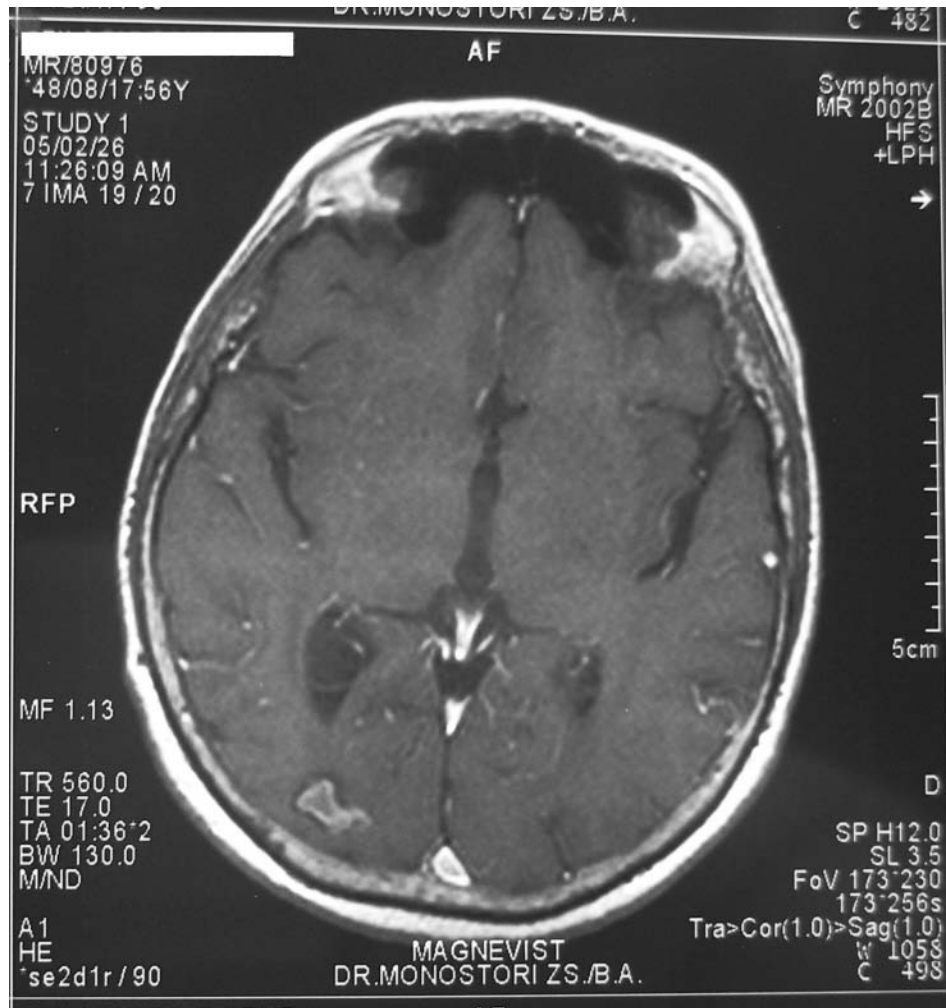The lung NSCLC adenocarcinoma had been excised and the lung process had been in remission for 4 years,

when 2 cerebral metastases developed and caused serious impairment of psychomotor speed and cognitive functions. The patient was treated with DDW for 951 days and monitored for a total of 1003 days. The combined treatment resulted in the disappearance (CR) of one brain metastasis and in PR of the other.

## Discussion

To obtain evidence to indicate the anticancer effect of D depletion, more than 1500 cancer patients have undergone DDW treatment since the Hungarian National Institute of Pharmacy authorized its application for compassionate use in the advanced stages of cancer. The present retrospective study was conducted on 4 patients whose brain metastasis deriving from lung cancer was present when DDW treatment started and surgery had not previously resulted in CR.





**Figure 3.** Anteroposterior computed tomography (CT) image of the brain metastasis from lung cancer in patient 2 during the prolonged deuterium depleted water (DDW) consumption, 1290 days after the first diagnosis. As a result of the prolonged DDW consumption after the completion of the radiotherapy and chemotherapy, complete remission with residual tissue is shown in the affected area.

Despite the limitations of this case-based, retrospective evaluation, the study might provide valuable information on the new treatment modality of D depletion. Further investigations are required to gain more insight into the possible anticancer properties of DDW.

Lung cancer possesses a high metastatic rate to the brain that increases the number of sufferers and the mortality rate in cancer patients. The life expectancy of these patients is limited and as a consequence of aggressive conventional treatment, serious side effects may also occur.<sup>22</sup> DDW treatment itself did not cause serious side effects. The anticancer effect and the safety of D depletion were also confirmed in a human phase II clinical trial on prostate cancer.<sup>18</sup> Although transient side effects might have occurred when DDW consumption was initiated or when the D content of DDW was reduced, all of these events ceased spontaneously at each given dose of DDW.

Patients with brain metastases are also at risk of several major medical complications that are not side effects.<sup>22</sup> These complications, such as increased intracranial pressure, superior vena cava syndrome, and thrombophlebitis, were observed in the present study. In spite of the advanced primary tumor and/or the multiple brain metastases accompanied by serious concomitant syndromes, the status of all involved patients improved remarkably when they consumed DDW in addition to conventional forms of treatment. The combined treatment resulted in CR or PR of the brain metastases or halted the continuous progression that could not have been stopped using conventional forms of treatment on their own. The evaluation also showed that the patients achieved a remarkably long survival time. As far as we are aware, survival times of 9.7, 26.6, 33.4, and 54.6 months are unique in the annals of brain metastases from lung tumors.

**Table 4.** Summary of the Case History of Patient 3

Date	Status	DDW Treatment	Conventional Therapy	Notes
December 2001	4 brain metastases, NSCLC, adrenal gland metastasis	None	Excision of 1 brain metastasis, whole brain irradiation, chemotherapy	
December 2001	PD, spreading to the left supraclavicular lymph node, superior caval vein syndrome	None	Chemotherapy	Predicted life expectancy of 3 weeks
January 2002		105 ppm	Chemotherapy	
March 2002		120 ppm (inappropriate dilution)	Chemotherapy	
April 2002		62 ppm	Chemotherapy	The patient led active life, endured gentle physical exercise
May 2002	PR mediastinum, NC lung	50 ppm	Chemotherapy	
August 2002	PD lung and mediastinum	37 ppm	End of chemotherapy, radiotherapy (thorax)	End of follow-up

NOTES: DDW = deuterium depleted water; NSCLC = non-small cell lung carcinoma; PD = progressive disease; PR = partial response; NC = no change.

**Table 5.** Summary of the Case History of Patient 4

Date	Status	DDW Treatment	Conventional Therapy	Notes
December 2001	2 brain metastases (left temporal and right frontoparietal), inoperable	105 ppm	Dehydration, stereotactic irradiation	NSCLC in remission for 4 years, increased intracranial pressure
January 2002		85 ppm		
March 2002	PR both brain metastases	65 ppm		
April 2002	PR left temporal, CR right frontoparietal metastasis	65 ppm		
May 2002	PR brain continued	65 ppm		
August 2002	PR brain continued	65 ppm		Reasonable physical status
September 2002	PR brain continued	25 ppm and then interruption	Excision of the left temporal tumor	
January 2003	PD brain, 2 new metastases	105 ppm	Stereotactic brain irradiation	
March 2003	PR brain	85 ppm		
May 2003	NC brain	75 ppm		
July 2003		62 ppm		
September 2003	PD increase in size, new brain metastasis	62 ppm	Stereotactic brain irradiation	
November 2003	PD contralateral lung metastasis	62 ppm	Chemotherapy, thoracic irradiation	
February 2004	PR lung	62 ppm	Chemotherapy, thoracic irradiation	
May 2004	PD new brain metastasis	62 ppm	End of chemotherapy and radiotherapy	
June 2004		25 ppm		
July 2004	Slow, but continuous PD	End of DDW treatment		
September 2004	The patient died			

NOTES: DDW = deuterium depleted water; NSCLC = non-small cell lung carcinoma; PR = partial response; CR = complete response; PD = progressive disease; NC = no change.

## Conclusion

We suggest that the integration of DDW treatment into conventional forms of therapies might provide a new therapeutic option for cancer patients, including those with advanced primary lung cancer and/or multiple brain metastases.

## Financial Disclosure

Research, development and drug registration process of deuterium-depleted water (DDW) is managed by the HYD LLC for Cancer Research and Drug Development. The HYD LLC has had DDW approved and registered for veterinary purposes under the name Vetera DDW-25, which has been commercially available in Hungary since 1999. The authors, Krisztina Krempels, Ildikó Somlyai and Gábor Somlyai are employees and Gábor Somlyai is also owner of the HYD LLC. Patients whose case histories are presented in this paper obtained Preventa from commercial sources. The employees of the HYD LLC provided assistance to each patient in the initiation and adjustment of the DDW consumption during the follow up, so that the combination of DDW treatment and conventional forms of therapies would achieve the best efficacy.

## References

1. Bajaj GK, Kleinberg L, Terezakis S. Current concepts and controversies in the treatment of parenchymal brain metastases: improved outcomes with aggressive management. *Cancer Invest.* 2005;23:363-376.
2. Fujimaki T. Surgical treatment of brain metastasis. *Int J Clin Oncol.* 2005;10:74-80.
3. Bajard A, Westeel V, Dubiez A, et al. Multivariate analysis of factors predictive of brain metastases in localised non-small cell lung carcinoma. *Lung Cancer.* 2004;45:317-323.
4. Hu C, Chang EL, Hassenbusch SJ 3rd, et al. Nonsmall cell lung cancer presenting with synchronous solitary brain metastasis. *Cancer.* 2006;106:1998-2004.
5. Jawahar A, Matthew RE, Minagar A, et al. Gamma knife surgery in the management of brain metastases from lung carcinoma: a retrospective analysis of survival, local tumor control, and freedom from new brain metastasis. *J Neurosurg.* 2004;100:842-847.
6. Sheehan J, Kondziolka D, Flickinger J, Lunsford LD. Radiosurgery for patients with recurrent small cell lung carcinoma metastatic to the brain: outcomes and prognostic factors. *J Neurosurg.* 2005;102(suppl):247-254.
7. Poon AN, Ho SS, Yeo W, Mok TS. Brain metastasis responding to gefitinib alone. *Oncology.* 2004;67:174-178.
8. Namba Y, Kijima T, Yokota S, et al. Gefitinib in patients with brain metastases from non-small-cell lung cancer: review of 15 clinical cases. *Clin Lung Cancer.* 2004;6:123-128.
9. Sugimura H, Yang P. Long-term survivorship in lung cancer: a review. *Chest.* 2006;129:1088-1097.
10. Kawamura H, Nakayama Y, Ishikawa H, et al. An eight-year survivor with multiple brain metastases of non-small cell lung cancer: an autopsy case. *Anticancer Res.* 2006;26:605-609.
11. Katz JJ, Crespi HL. Isotope effects in biological systems. In: Collins CJ, Bowman NS, eds. *Isotope Effects in Chemical Reactions.* New York, NY: Van Nostrand Reinhold; 1971:286-363.
12. Rundel PW, Ehleringer JR, Nagy KA. *Stable Isotopes in Ecological Research.* New York, NY: Springer; 1988.
13. Jancsó G. Isotope effects. In: Vértes A, Nagy S, Klencsár Z, eds. *Handbook of Nuclear Chemistry, Volume 2.* Dordrecht, Netherlands: Kluwer Academic; 2003:85-116.
14. Somlyai G, Jancsó G, Jákli G, et al. Naturally occurring deuterium is essential for the normal growth rate of cells. *FEBS Lett.* 1993;317:1-4.
15. Somlyai G, Laskay G, Berkényi T, et al. Naturally occurring deuterium may have a central role in cell signalling. In: Heys JR, Melillo DG, eds. *Synthesis and Applications of Isotopically Labelled Compounds.* New York, NY: John Wiley and Sons; 1998:137-141.
16. Somlyai G, Laskay G, Berkényi T, et al. The biological effects of deuterium-depleted water, a possible new tool in cancer therapy. *Z Onkol/J Oncol.* 1998;30:91-94.
17. Gyöngyi Z, Somlyai G. Deuterium depletion can decrease the expression of c-myc, Ha-ras and p53 gene in carcinogen-treated mice. *In Vivo.* 2000;14:437-439.
18. Somlyai G, Jancsó G, Jákli G, Berkényi Z, Gyöngyi I. The biological effect of deuterium depleted water, a possible new tool in cancer therapy. *Anticancer Res.* 2001;21:1617.
19. Katz JJ, Crespi HL, Czajka DM, Finkel AJ. Course of deuteration and some physiological effects of deuterium in mice. *Am J Physiol.* 1962;203:907-913.
20. London H, ed. *Separation of Isotopes.* London, UK: George Newnes; 1961.
21. Gaspar LE, Scott C, Murray K, Curran W. Validation of the RTOG recursive partitioning analysis (RPA) classification for brain metastases. *Int J Radiat Oncol. Biol. Phys.* 2000;47:1001-1006.
22. Pruitt AA. Treatment of medical complications in patients with brain tumors. *Curr Treat Options Neurol.* 2005;7:323-336.